

# The Proximal Opening Wedge Osteotomy for the Correction of Hallux Valgus Deformity

Troy S. Watson, MD and Paul S. Shurnas, MD✱

**Abstract:** Many surgical procedures exist to correct metatarsus primus varus associated with hallux valgus deformity. Among these procedures are various first metatarsal osteotomies. Both distal and proximal osteotomies have been described to correct these deformities with the latter typically used for the more severe deformity. The goal of the operative procedure is correction of the intermetatarsal and hallux valgus angles with restoration of pain-free shoe wear. The complications associated with the various described proximal metatarsal osteotomies are many, and the techniques can be technically demanding, especially for the surgeon without assistance in the operating room. Although generally good results are observed with traditional osteotomies, the complication rate remains high, leading many surgeons to search for alternative means for correcting these deformities. In this paper, we review a novel technique with a proximal opening wedge osteotomy of the first metatarsal for the correction of moderate-to-severe hallux valgus deformity.

**Keywords:** bunion, proximal osteotomy, hallux valgus, opening wedge osteotomy, metatarsal

(*Tech Foot & Ankle* 2012;11: 168–174)

## HISTORICAL PERSPECTIVE

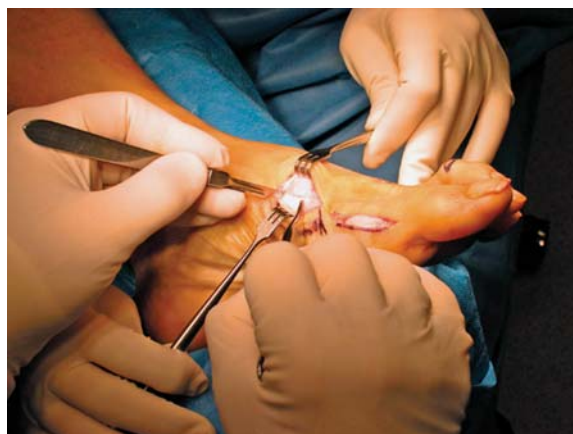The treatment of moderate-to-severe hallux valgus deformity (hallux valgus angle [HVA], >20 degrees; intermetatarsal angle [IMA], >13 degrees) usually necessitates use of either a proximal metatarsal osteotomy or a metatarsocuneiform arthrodesis combined with a distal soft tissue procedure.<sup>1</sup> Many proximal osteotomies have been described, each advocated for its ability to correct the larger deformities and each with their unique complications. A number of proximal osteotomies have been studied including the crescentic,<sup>2</sup> the scarf,<sup>3</sup> the Ludloff,<sup>4</sup> the chevron,<sup>5,6</sup> the closing wedge lateral osteotomy,<sup>7</sup> and now, the medial opening wedge.<sup>8,9</sup> The surgeon's continued search for the ideal proximal osteotomy is fueled by the need to find a procedure technically easy to perform that has a low complication rate, a sturdy construct allowing early weight bearing and high patient satisfaction. With the introduction of new proximal metatarsal osteotomy plates, the technique for the medial opening wedge osteotomy is less demanding and may meet these criteria for the ideal proximal osteotomy.

Little has been written about the proximal first metatarsal osteotomy. In the past, studies evaluating this osteotomy were typically done for adolescent bunions; therefore, the high recurrence rates quoted may be biased by this patient population.<sup>10–12</sup> Limbird et al<sup>9</sup> treated 22 feet with an average preoperative IMA

of 15 degrees correcting to 8 degrees postoperatively. All osteotomies healed within 3 months with excellent cosmetic and functional results. Wukich et al<sup>13</sup> reported on 14 patients using a proximal metatarsal opening wedge osteotomy and noted excellent correction, no recurrence, and high patient satisfaction. Cooper et al<sup>8</sup> published their results of 23 patients with a proximal opening wedge osteotomy fixed with a low profile plate. Preoperatively, the HVA and IMA were 33 and 18 degrees, respectively, correcting to 18 and 11 degrees, respectively, postoperatively. There was 1 delayed union and 2 incidences of drifting of the HVA of greater than 5 degrees. There were no reports of hallux varus in this study. Lastly, Shurnas<sup>14</sup> reported his series of 50 patients treated with a proximal opening wedge osteotomy. Excellent correction was obtained, and no reports of nonunion, malunion, or delayed union were reported. There were 2 cases of recurrence, with 1 necessitating a second procedure, and 5 cases of hallux varus, with 1 requiring revision surgery. Additionally, biomechanical testing in the laboratory comparing the proximal chevron osteotomy with the opening wedge osteotomy fixed with a plate showed no difference in load to failure, ultimate strength, or stiffness. Potential problems with this osteotomy are lengthening of the first metatarsal, a higher rate of recurrence versus traditional osteotomies, hallux varus, and decreased stability at the osteotomy site. Long-term follow-up with greater numbers will be necessary to better compare this osteotomy with the previously mentioned osteotomies.

## INDICATIONS/CONTRAINDICATIONS

The indications for the use of the first metatarsal proximal opening wedge osteotomy are a hallux valgus deformity with a first-second intermetatarsal angle of 13 degrees or greater. Contraindications to this technique are first-ray hypermobility, an arthritic first tarsometatarsal (TMT) joint and painful hallux metatarsophalangeal (MTP) joint arthrosis. Relative



**FIGURE 1.** Percutaneous incisions over the medial eminence and dorsal medial base of the first metatarsal.

*At the time of the original publication:*

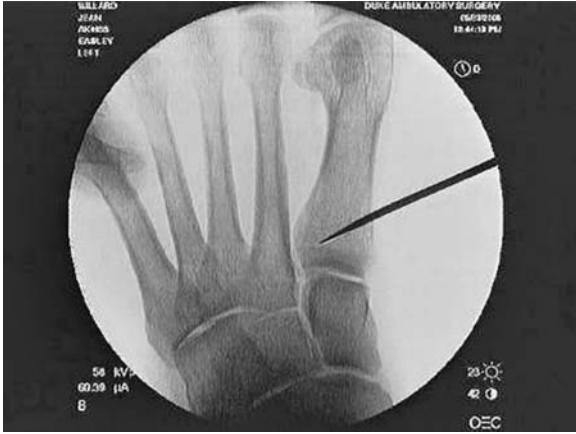From the Desert Orthopaedic Center Foot and Ankle Institute Las Vegas, NV; and The Columbia Orthopaedic Group Foot and Ankle Institute Columbia, MO.

✱Deceased.

Address correspondence and reprint requests to Troy S. Watson, MD, 2800 E Desert Inn Rd, Suite 100, Las Vegas, NV 89121. E-mail: feetmd@gmail.com.

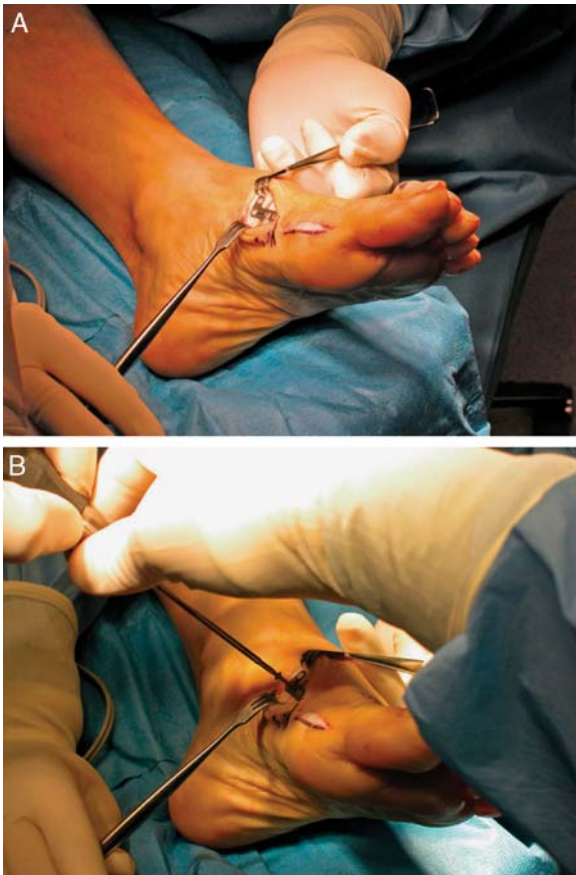
Reprinted with permission from Watson TS, Shurnas PS. The proximal opening wedge osteotomy for the correction of hallux valgus deformity. *Tech Foot & Ankle*. 2008;7:17–24.

Copyright © 2012 by Lippincott Williams & Wilkins

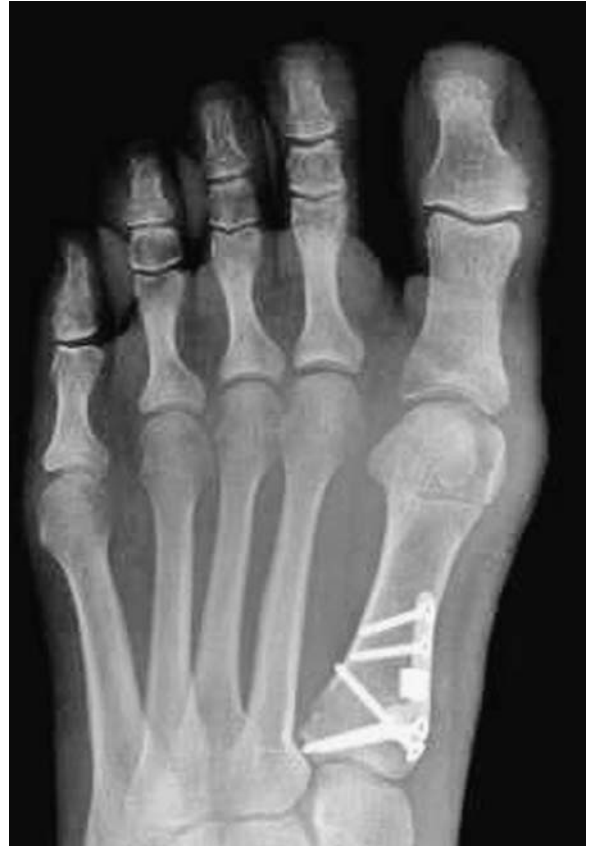

**FIGURE 2.** Radiograph demonstrates the orientation and starting point of the osteotomy.

contraindications are age greater than 60, osteoporosis, inflammatory arthropathies, neuromuscular disorders, and severe first-second IMAs (>20 degrees). Patients with a severe IMA may still be treated with an opening wedge osteotomy but may also require adjunct procedures such as a distal chevron osteotomy.



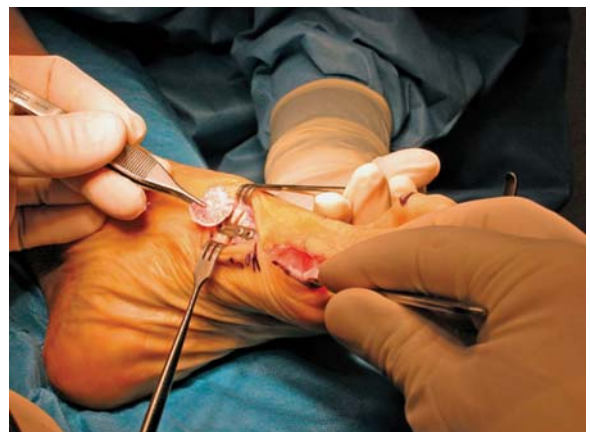**FIGURE 3.** A, Placement of the LPS opening wedge plate in the osteotomy site. B, The first screw is placed in the most proximal of the distal screw holes to set the plate.



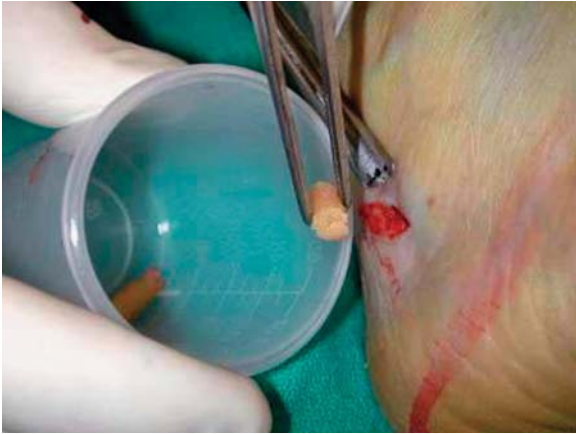**FIGURE 4.** Radiograph showing placement of proximal screws in the proximal segment of the osteotomy and additional screw outside the plate for enhanced fixation of the apex of the osteotomy. The authors prefer to place the proximal screws across the apex of the osteotomy.

**PREOPERATIVE PLANNING**

The preoperative assessment of the patient presenting with hallux valgus begins with a careful history. Attention to the onset of deformity helps distinguish adolescent bunions, which may have a greater tendency toward recurrence. It is important to confirm with the patient that adequate conservative



**FIGURE 5.** The medial eminence excised is usually sufficient bone graft for the osteotomy site.

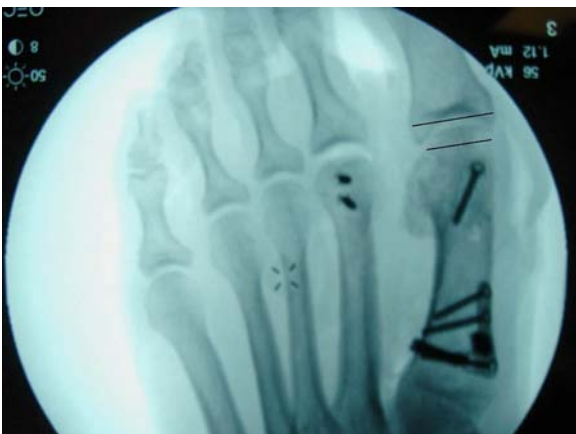

**FIGURE 6.** Alternative method using cancellous graft from the calcaneus for the osteotomy site.

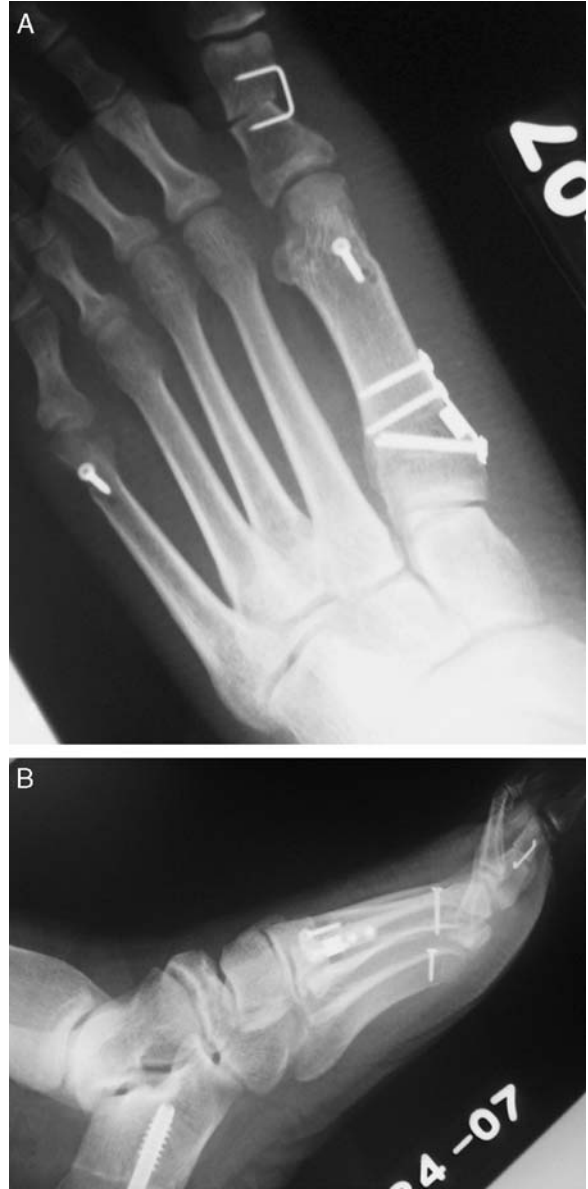measures have been trialed including wide toe-box shoes. Additionally, a patient being considered for surgical intervention should demonstrate pain over the medial eminence or lesser toe pathology as a result of the hallux valgus deformity. Scheduling patients for surgery strictly to correct cosmetic deformities is not recommended because this can lead to a painful condition postoperatively.

A history of inflammatory arthritis or neuromuscular disease can affect the decision making for operative procedure used to correct the deformity, and arthrodesis of the first MTP joint is usually recommended.

Physical examination in the office should include an assessment of the patient’s gait, looking for associated hindfoot deformities such as flatfoot and forefoot deformities including pronation of the great-toe and lesser-toe deformities. This is followed by inspection of the foot, with attention to the plantar aspect of the lesser MTP joints. Calluses and pain to palpation underlying this area may be an indication of pathology, which may need to be addressed concomitantly with the bunion procedure. On occasion, this metatarsalgia may be the patient’s presenting complaint rather than the bunion. Manipulation of the hallux MTP joint will determine the presence of hallux rigidus, which may be a contraindication to an osteotomy. Additionally, examination for first-ray hypermobility should be completed at this time. If present, the patient may be better



**FIGURE 7.** Radiograph shows reduction of the distal metatarsal articular angle using a biplanar chevron osteotomy.

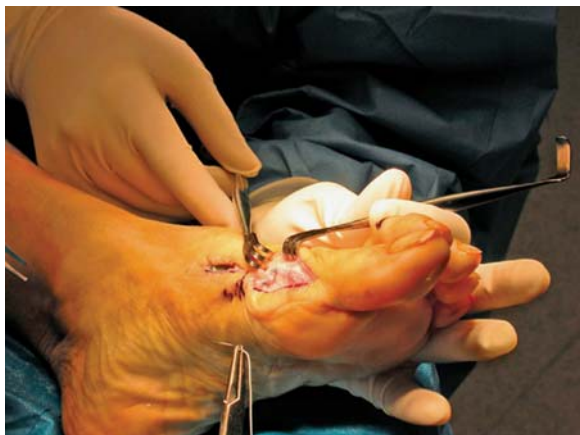

**FIGURE 8.** Radiograph shows a triple osteotomy for a juvenile hallux valgus deformity with associated plano-valgus correction.

treated with a Lapidus-type procedure. Patients will often present with nerve irritation along the course of the superficial cutaneous nerve because it courses over the medial eminence. This symptom typically improves with surgical correction of the bunion but should be noted preoperatively. Finally, lesser toe deformities are noted and discussed with the patient for possible correction.

After a careful history and physical examination of the foot, standing anteroposterior and lateral radiographs are assessed. The HVAs and IMAs are measured; and sesamoid position, noted. The HVA should not exceed 15 degrees, and the IMA should not be greater than 9 degrees. Evaluation of the distal metatarsal articular angle (DMAA) should be done. A DMAA of greater than 15 degrees is considered abnormal and may need to be addressed with a distal biplanar osteotomy. Moving proximally, the first TMT joint is inspected for





**FIGURE 9.** Capsular repair is shown using a nonabsorbable suture.

arthrosis. On the lateral radiograph, special attention to gapping of greater than 2 mm at the first TMT joint may indicate hypermobility.

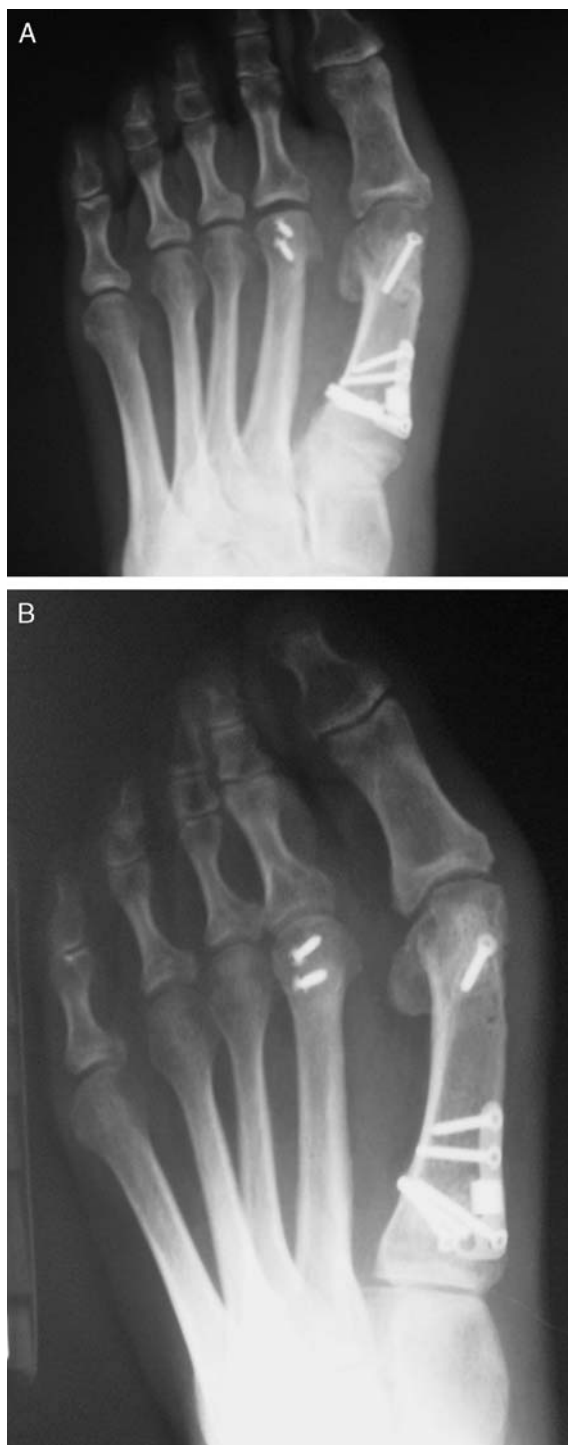### TECHNIQUE

A 2- or 3-incision technique may be used. The authors prefer to make a 3-cm longitudinal incision over the medial eminence and dorsal medial base of the first metatarsal (Fig. 1). The bunion is usually approached first.

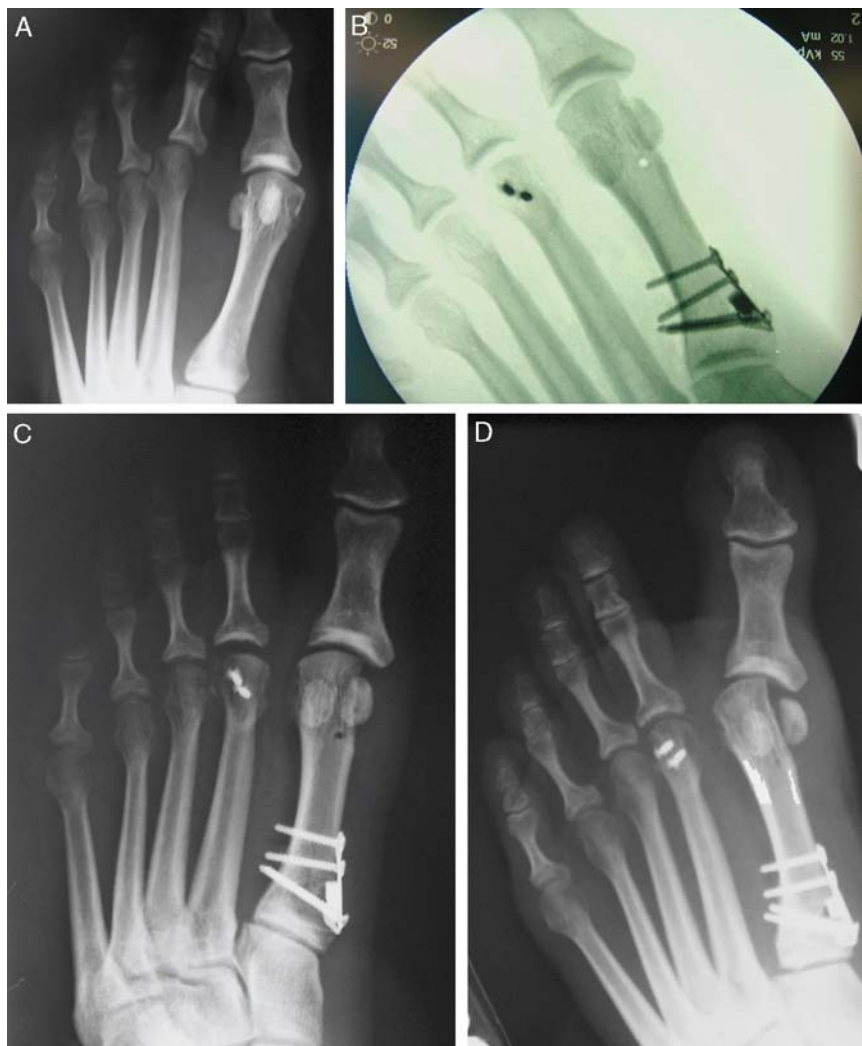Dorsal and plantar neurovascular structures are retracted, and an inverted L-shaped capsulotomy is reflected, exposing the medial eminence. The bunion is resected with a saw, beginning the cut 1 to 2 mm medial to the sulcus. The cut surface is beveled with a rongeur, and any dorsal prominence is resected in a similar fashion. The lateral capsule and adductor tendon are released by “pie crusting” the tissue through the joint so that approximately 10 to 15 degrees of varus correction is achieved with manipulation. As an alternative, a small mini-incision technique may be used over the first web space to release the adductor tendon. Care must be taken not to be overzealous with the lateral release that may lead to an increased incidence of hallux varus. The excised medial eminence is prepared on the back table for autograft and will be impacted into the proximal osteotomy.

An oblique proximal osteotomy is made, beginning the cut approximately 1.5 cm distal to the first metatarsocuneiform joint with the blade oriented perpendicular to the long axis of the metatarsal and aimed at the corner of the proximal lateral first metatarsal flare (Fig. 2). The osteotomy is stopped short of the lateral cortex and may be verified with imaging if needed. Three osteotomes from the Arthrex low profile plate and screw system (LPS) set are used sequentially to open the osteotomy site, and the mini lamina spreader is placed in the dorsal medial cortical opening to help obtain correction and facilitate placement of the plate. Based on clinical results with this technique, approximately 2 to 3 degrees of correction in the IMA are obtained for each millimeter of opening wedge. Alternatively, a trial opening wedge is available in the set or the mini lamina spreader can be used to obtain correction that can then be verified with imaging. The appropriately sized plate is placed into the osteotomy site, and the most proximal of the distal screw holes is used for fixation (Fig. 3) (an 18-mm screw is typical). With the plate now set, the proximal screws are inserted either across the apex of the osteotomy or in the

proximal metatarsal segment (Fig. 4). An oblique screw outside the plate may be used for additional fixation (Fig. 4). The autograft from the medial eminence is impacted into the



**FIGURE 10.** A, Early valgus drift due to poor capsular tissue in a patient undergoing chemotherapy for breast cancer. B, Continued valgus drift with no obvious change in the IMA, no loss of fixation and good bone healing. A drill hole was utilized for the capsule repair.



**FIGURE 11.** A, Preoperative radiograph. B, Postoperative fluoroscopy demonstrates good correction. C, Early follow-up with maintained alignment. D, Patient took off cam boot at 3 weeks postoperatively and felt a “pop” resulting in severe varus deformity.

osteotomy site (Fig. 5), or alternatively, autograft may be harvested from the calcaneus (Fig. 6).

The correction is verified with imaging, and the DMAA was evaluated. Congruent joints, juvenile deformities, and joints with increased DMAA are treated with the addition of a distal biplanar chevron (Fig. 7). Hallux interphalangeus is treated with an Akin osteotomy (Fig. 8). With the toe held in neutral rotation and valgus, the joint capsule is repaired through a dorsal-plantar drill hole made at the metaphyseal-diaphyseal junction, with suture alone or suture anchor as needed (Fig. 9).

**POSTOPERATIVE MANAGEMENT**

A bulky gauze and a flexible self-sticking wrap is placed in the operating room, and the extremity is fit and immobilized into a short cam walking boot. Weight bearing, as tolerated, is allowed, and the dressings are changed in 3 to 5 days to a Coban and gauze wrap figure-of-eight dressing that the patient can change. Sutures are removed 2 weeks postoperatively, and the dressing is changed to a gauze and Velcro soft bunion splint. The soft bunion splint is worn until the 6-week postoperative visit when

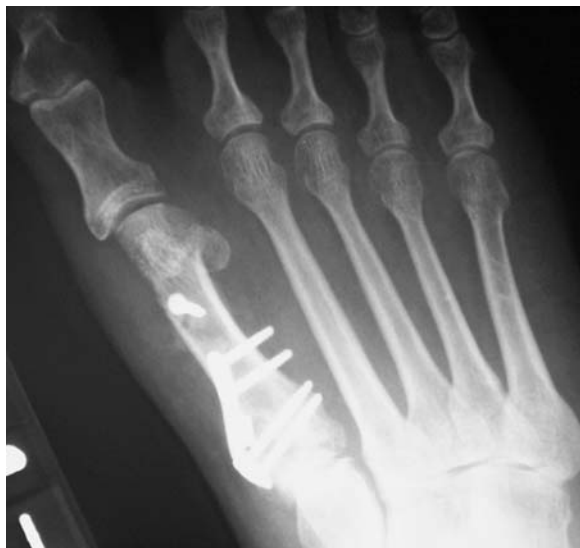radiographs confirm healing so that patients can transition to regular shoe wear. Most patients are in regular tennis shoes by 8 weeks, and fashionable shoes after 10 weeks are allowed.

Active and passive range of motion to the MTP joint is started after the first postoperative visit. Patients are encouraged to perform range of motion exercises in the dressings but are allowed to come out of the dressings if needed.

**RESULTS**

Most proximal osteotomies have complications including loss of fixation, first-ray shortening, elevation, nonunion, delayed union, malunion, and overcorrection into varus. The ideal procedure would provide reliable, measurable, and powerful correction, yielding predictable results with technical ease.

Opening wedge osteotomy using the Arthrex LPS system has been compared with proximal chevron osteotomy using 5 matched pairs of cadaveric feet (mean age, 48 years). 14 Standard technique and fixation were used (a 4.0-mm small fragment stainless screw and 0.62-mm Kirschner wire was used for the chevron). First-ray specimens were potted and



**FIGURE 12.** Double osteotomy of a severe hallux valgus deformity using a biplanar chevron osteotomy for correction of the DMAA and to obtain further correction of the deformity.

fixed, and Instron testing was performed to determine ultimate load to failure, stiffness, and load versus displacement. There were no cases of hardware failure in either group. At maximal load, the lateral cortex failed with the LPS construct, whereas 4 of 5 screws and Kirschner wires pulled out of the bone, and 1 metatarsal fractured in the chevron group. There was no significant difference in ultimate load to failure, stiffness, or in other measured parameter between osteotomy types.

Clinically, more than 100 patients have been evaluated. Seventy patients have more than 2 years of follow-up. Patients with inflammatory conditions, hindfoot and midfoot deformity, and moderate-to-severe arthritis were excluded.

The results of the first 50 patients treated with this technique have been reported. 14 The mean age was 44 years (range, 13-80 years), and the mean follow-up was 1 year in 25 patients and 6 months to 1 year in 25 patients. Moderate-to-severe deformities were treated (mean preoperative IMA, 15 degrees [range, 14-20 degrees]; mean preoperative HVA, 31 degrees [range, 25-40 degrees]), and no patient had prior bunion surgery. All patients rated their result as good or excellent, but there were 2 cases of varus (5 degrees). Mean range of total MTP motion was 76 degrees (range, 45-75 degrees), and there was a mean loss of 13 degrees of total MTP motion (range, 0-20 degrees). A mean of 3-degree correction per millimeter of opening wedge was achieved. The mean decrease in IMA and HVA were 12 and 20 degrees, respectively, and the mean postoperative IMA and HVA were 3 and 11 degrees, respectively. The mean time to radiographic union was 5.8 weeks. There were no cases of nonunion, shortening (mean increase in protrusion distance was 2 mm), elevatus, malunion, failure, or recurrence.

The results of the proximal opening wedge osteotomy using the Arthrex LPS plate and the Darco locking plate have been compared. 8 Osteotomy was made 1 cm distal to the first TMT joint, with a flat instead of oblique cut, and the mean correction was 1.5 degrees per millimeter of opening wedge. Mean increase in first metatarsal length or protrusion was 2 millimeters; there were 2 cases of valgus drift of more than 5 degrees but no cases of varus, malunions, or nonunions and no differences between correction obtained or fixation between plate types.

More experience with the technique has been gained, and the overall success rate remains high in more than 100 cases in the authors' practices, but there have been concerns. One case of severe varus and 2 cases of recurrence (valgus drift of >5 degrees) have occurred. Symptomatic hardware has been removed in 12 patients.

## COMPLICATIONS

The cases of recurrence are felt to be due to capsule repair failure or poor capsular tissue (Fig. 10), and radiographs demonstrate no change in IMA but increased HVA, with sesamoid position relatively maintained. The capsule is routinely repaired using a drill hole made at the metaphyseal-diaphyseal junction and nonabsorbable suture. Most cases of recurrence were noted to have poor capsular tissue at the time of surgery.

The case of severe varus was presumably related to overrelease laterally in a patient that was walking several miles in regular shoes at 3.5 weeks postoperatively (Fig. 11). The technique described in this paper is a modification of the original. We no longer advocate the routine use of an aggressive lateral release but one which can be done through the joint or with a smaller mini web space incision.

## FUTURE OF TECHNIQUE

This is a promising technique; however, prospective studies are needed for more detailed analysis, and the long-term results are unknown. To minimize hardware removal and achieve truly uniplanar correction, the plate should be applied laterally toward the plantar ridge of the metatarsal base. Despite its low profile, approximately 10% of patients complain of prominence, and locking designs being evaluated are even bulkier and will likely require a higher rate of removal.

Biomechanically, the plate is as stable as the proximal chevron osteotomy, but there may be a limit to the maximal correction obtained because wedges of more than 6 mm demonstrate no further correction. However, using an oblique cut as described in this paper and a 6-mm wedge allowed for a mean correction of 18 degrees in the IMA (range, 15-20 degrees). Adding a distal biplanar chevron osteotomy (Fig. 12) allows further correction and addresses an increased DMAA. It should be stressed that long-term follow-up will be necessary to determine any effect at the first TMT joint such as subluxation or degenerative changes. Early results indicate that this does not seem to be the case.

## REFERENCES

1. Coughlin M, Mann R. Hallux valgus. In: Coughlin M, Mann R, Saltzman C, eds. *Surgery of the Foot and Ankle*. 8th ed. St Louis: CV Mosby; 2007:183-362.
2. Mann R, Rudicel S, Graves S. Repair of hallux valgus with a distal soft tissue procedure and proximal metatarsal osteotomy. A long-term follow-up. *J Bone Joint Surg Am*. 1992;74:124-129.
3. Miller JM, Stuck R, Sartori M, et al. The inverted Z bunionectomy: quantitative analysis of the scarf and inverted scarf bunionectomy osteotomies in fresh cadaveric matched pair specimens. *J Foot Ankle Surg*. 1994;33:455-462.
4. Saxena A, McCammon D. The Ludloff osteotomy: a critical analysis. *J Foot Ankle Surg*. 1997;36:100-105; discussion 159-160.
5. Easley ME, Kiebzak GM, Davis WH, et al. Prospective, randomized comparison of proximal crescentic and proximal chevron osteotomies for correction of hallux valgus deformity. *Foot Ankle Int*. 1996;17:307-316.

6. Sammarco GJ, Brainard BJ, Sammarco VJ. Bunion correction using proximal chevron osteotomy. *Foot Ankle*. 1993;14:8–14.
7. Nigro JS, Greger GM, Catanzariti AR. Closing base wedge osteotomy. *J Foot Surg*. 1991;30:494–505.
8. Cooper M, Berlet G, Shurnas P, et al. Proximal opening wedge osteotomy of the first metatarsal for correction of hallux valgus. *Surg Technol Int*. 2007;16:215–219.
9. Limbird TJ, DaSilva RM, Green NE. Osteotomy of the first metatarsal base for metatarsus primus varus. *Foot Ankle*. 1989;9:158–162.
10. Bonney G, Macnab I. Hallux valgus and hallux rigidus; a critical survey of operative results. *J Bone Joint Surg Br*. 1952;34:366–385.
11. Goldner JL, Gaines RW. Adult and juvenile hallux valgus: analysis and treatment. *Orthop Clin North Am*. 1976;7:863–887.
12. Scranton PE Jr, Zuckerman JD. Bunion surgery in adolescents: Results of surgical treatment. *J Pediatr Orthop*. 1984;4:39–43.
13. Wukich DK, Roussel AJ, Dial D. Opening wedge osteotomy of the first metatarsal base: a technique for correction of metatarsus primus varus using a new titanium opening wedge plate. *Oper Tech Orthop*. 2006;16:76–81.
14. Shurnas P. Proximal opening wedge osteotomy of the first metatarsal: biomechanical and clinical evaluation. Proceedings of the AAOS Annual Meeting, Specialty Day; 2006; Chicago, IL.