

Foot & Ankle International

<http://fai.sagepub.com/>

Correction of Moderate to Severe Hallux Valgus With Isometric First Metatarsal Double Osteotomy

Werner Siekmann, Troy S. Watson and Matthias Roggelin
Foot Ankle Int 2014 35: 1122 originally published online 23 July 2014
DOI: 10.1177/1071100714544520

The online version of this article can be found at:

<http://fai.sagepub.com/content/35/11/1122>

Published by:



<http://www.sagepublications.com>

On behalf of:



[American Orthopaedic Foot & Ankle Society](#)

Additional services and information for *Foot & Ankle International* can be found at:

Email Alerts: <http://fai.sagepub.com/cgi/alerts>

Subscriptions: <http://fai.sagepub.com/subscriptions>

Reprints: <http://www.sagepub.com/journalsReprints.nav>

Permissions: <http://www.sagepub.com/journalsPermissions.nav>

>> [Version of Record](#) - Nov 3, 2014

[OnlineFirst Version of Record](#) - Jul 23, 2014

[What is This?](#)

Correction of Moderate to Severe Hallux Valgus With Isometric First Metatarsal Double Osteotomy

Foot & Ankle International
2014, Vol. 35(11) 1122–1130
© The Author(s) 2014
Reprints and permissions:
sagepub.com/journalsPermissions.nav
DOI: 10.1177/1071100714544520
fai.sagepub.com

Werner Siekmann, MD¹, Troy S. Watson, MD²,
and Matthias Roggelin, MD¹

Abstract

Background: The operative treatment for the moderate to severe bunion continues to present challenges. The indications for a single, double, or triple first ray osteotomy remain controversial. In addition, it is not clear whether an opening wedge osteotomy leads to clinically relevant arthritis at the first metatarsophalangeal joint. However, it is this theoretical concern that has led the authors to develop an isometric correction of the first ray.

Methods: Thirty-two patients underwent operative correction of hallux valgus with a double osteotomy of the first metatarsal using an opening wedge proximally and a closing wedge distally. The mean follow-up period was 59.3 months with a range of 55 to 65 months.

Results: The 1-2 intermetatarsal angle preoperatively was a mean of 18.9 degrees (range 17-23), correcting postoperatively to a mean angle of 8.6 degrees (range 5-12), for an average correction of 10.4 degrees (range 6-16). The postoperative AOFAS scores were 39.4 out of 40 points for pain, 42.4 out of 45 points for function, and 15 points for alignment. The total score was excellent with 94.2 out of 100 possible points. Radiographic union occurred in all cases. There was one case of painful edema of the foot and two cases of early avascular necrosis (AVN) diagnosed by residual pain at the hallux metatarsophalangeal joint and transient osteopenia of the metatarsal head on radiographs. No late sequelae associated with AVN such as arthritis or metatarsal head collapse were noted with long-term follow-up. These healed within months without specific treatment.

Conclusion: A double osteotomy of the first metatarsal with a nonlocking, low-profile plate was an effective procedure for correcting severe hallux valgus that carried a low complication rate and high patient satisfaction. It has clear advantages over isolated opening wedge procedures, including potentially better correction especially in those bunions associated with an increased distal metatarsal articular angle.

Level of Evidence: Level IV, retrospective case series.

Keywords: hallux valgus, opening wedge osteotomy, double osteotomy

The operative treatment of moderate to severe hallux valgus presents various challenges for the surgeon. Despite the multitude of operative techniques and their combinations, the indications for single, double, or triple osteotomies remain muddled and treatment requires independent decisions for each foot.^{6,8-11,13,14,20,21,25} To correct a higher 1-2 intermetatarsal angle (IMA), a more proximal metatarsal osteotomy is necessary. Biomechanical studies have identified the alignment of the first tarsometatarsal joint to be of high importance in the development of hallux valgus.²⁸ Therefore, while preserving the tarsometatarsal joint, the proximal procedure realigns the first ray to a greater extent than a distal procedure is capable of doing. According to biomechanical studies,^{4,6} the differences in stiffness and stability of various osteotomy types^{3,12,22,23} have led to the development of a medially placed low-profile plate for a

proximal first metatarsal opening-wedge osteotomy.²⁴ The plate should be thin enough to be self-bending while stabilizing the opening wedge osteotomy.

The goal was to create a simple procedure, predictable to perform and with stable fixation. First steps with this plate (Figure 1) in 2003 made clear that independent of the fixation technique an isolated opening-wedge technique did not adequately address two problems:

¹Argon-Orthopaedie Hamburg, Hamburg, Germany

²Desert Orthopaedic Center, Las Vegas, NV, USA

Corresponding Author:

Troy S. Watson, MD, Desert Orthopaedic Center, 2800 Desert Inn Rd, Ste 100, Las Vegas, NV 89121, USA.
Email: feetmd@yahoo.com




Figure 1. The low-profile plate (Arthrex Inc) with a thickness of 0.5 mm allows contouring to the bone with placement of the screws. No bending is necessary.

1. The opening wedge effectively lengthens the first metatarsal and, in theory, places increased stresses at the hallux metatarsophalangeal joint. This increased stress may lead to long-term hallux metatarsophalangeal joint arthrosis and a poor outcome.
2. Although the opening wedge osteotomy effectively corrects the intermetatarsal angle (IMA), it does nothing to correct an abnormally high distal metatarsal articular angle (DMAA).

The challenge was to correct both deformities (DMAA and IMA) in one surgery without compromising the optimal outcome for each procedure,⁵ while avoiding lengthening of the first ray and increased pressure on the first metatarsophalangeal joint. The solution was a combination of the opening wedge technique proximally with a closing wedge (chevron technique named after Reverdin-Green) procedure distally (Figures 2A, 2B).

Methods

The study cohort included 40 patients who underwent a double osteotomy. Institutional review board approval was obtained for this retrospective study that required follow-up radiographs and a questionnaire. Eight patients were lost to follow-up, leaving 32 patients (19 right feet, 13 left feet) for evaluation after a double-osteotomy procedure of the first metatarsal (20% lost to follow-up). The mean follow-up was 50 months, ranging from 52 to 65 months.

A single surgeon performed all procedures. The ratio of males to females was 5 to 27. The mean age at the time of operation was 57 years, ranging from 40 to 77 years. The mean preoperative 1-2 IMA was 18.9 degrees, ranging from

15 to 23 degrees. All available patients were evaluated for postoperative follow-up by physical examination and completion of the AOFAS forefoot questionnaire. The level of osteoarthritis of the hallux metatarsophalangeal joint was assessed intraoperatively using a 4-grade scale (none, mild, moderate, severe).

Criteria for double osteotomy included patients with a 1-2 intermetatarsal angle between 15 and 25 degrees and with a DMAA in excess of 8 degrees (Figures 3A, 3B). Contraindications for this procedure were severe osteoarthritis of the hallux metatarsophalangeal joint, severe metatarsus adductus, severe osteoporosis, and clear instability of the first tarsometatarsal joint. Relative contraindications were a normal DMAA, severe obesity, and a relatively long first metatarsal.

Operative Procedure

A single incision technique was used with a curved incision anteromedially, allowing the surgeon to perform the adductor release as well as the osteotomies through this solitary approach. In addition, this incision offered an improved cosmetic appearance to the foot postoperatively over a dorsomedial incision. In all cases, a lateral release was performed by carefully releasing the adductor tendon from the base of the proximal phalanx as well as releasing it from the lateral aspect of the fibular sesamoid. No additional release of the lateral capsule was performed. About 15 mm distal to the first tarsometatarsal (TMT) joint, the proximal osteotomy was made with a sagittal saw blade taking care not to violate the lateral cortex. A straight perpendicular cut in the metatarsal or an oblique cut aimed slightly proximally was performed. The angled cut had the advantage of creating a more proximal pivot point and a parallel first and second metatarsal without separation.

The osteotomy was then carefully opened with 3 osteotomes, respecting the bio-elastic forces of the bone and soft tissues. The low-profile plate was then placed on the medial side of the first metatarsal as plantar as possible (Figures 4A-4E). Because of the resulting additional pressure across the hallux metatarsophalangeal joint due to the additional length of the first metatarsal,²⁶ as well as the increased DMAA, the distal closing wedge osteotomy as described by Reverdin-Green was used to address these issues.¹⁶ Therefore, an additional L-shaped chevron closing wedge osteotomy with a small lateral shift (Figures 5A-5C) was performed to correct the DMAA, reduce the bunion pathology and help compensate for the added length from the proximal procedure.^{1,2} In addition, the distal osteotomy might further reduce joint pressure if cartilage damage was noted intraoperatively or development of osteoarthritis in the future was of concern.⁷ The wedge that was removed distally was placed into the opening wedge proximally for stimulation of bone growth (Figure 6).

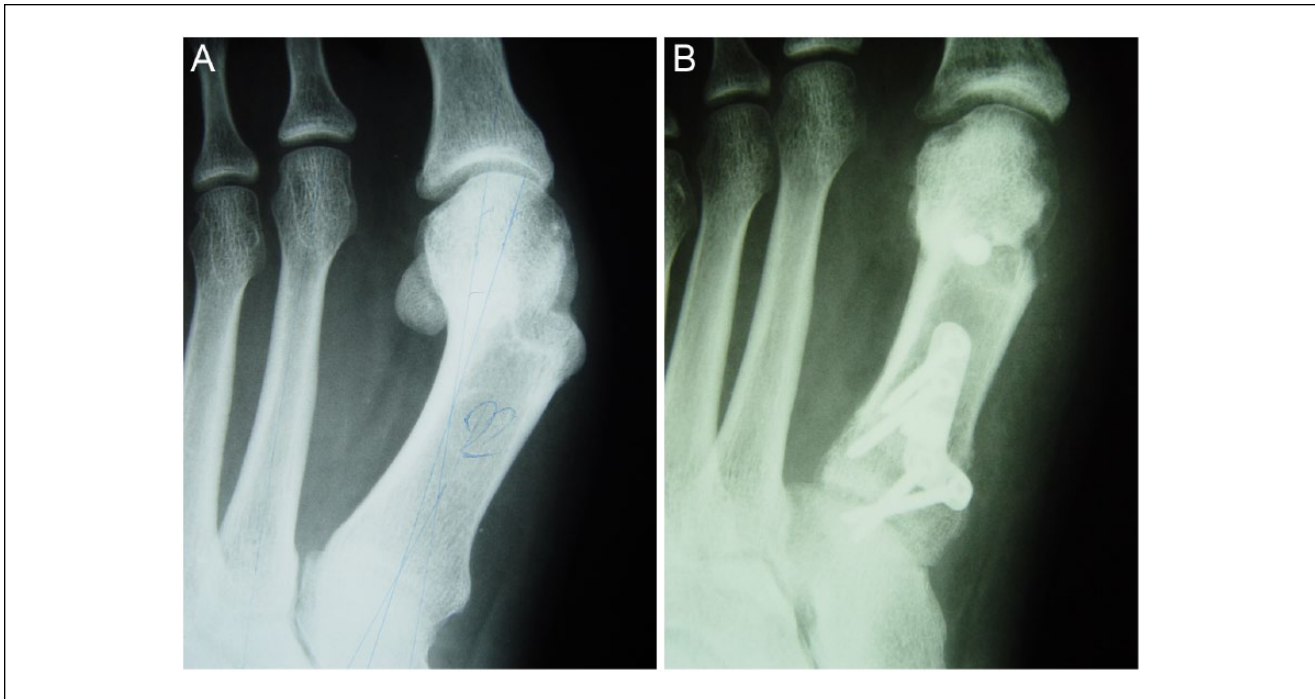

Figure 2. (A) Preoperative AP radiograph showing inadequate correction of a hallux valgus with a distal osteotomy. Note the residual high intermetatarsal angle. (B) Postoperative correction with double osteotomy technique showing correction of intermetatarsal angle and correction of the DMAA.

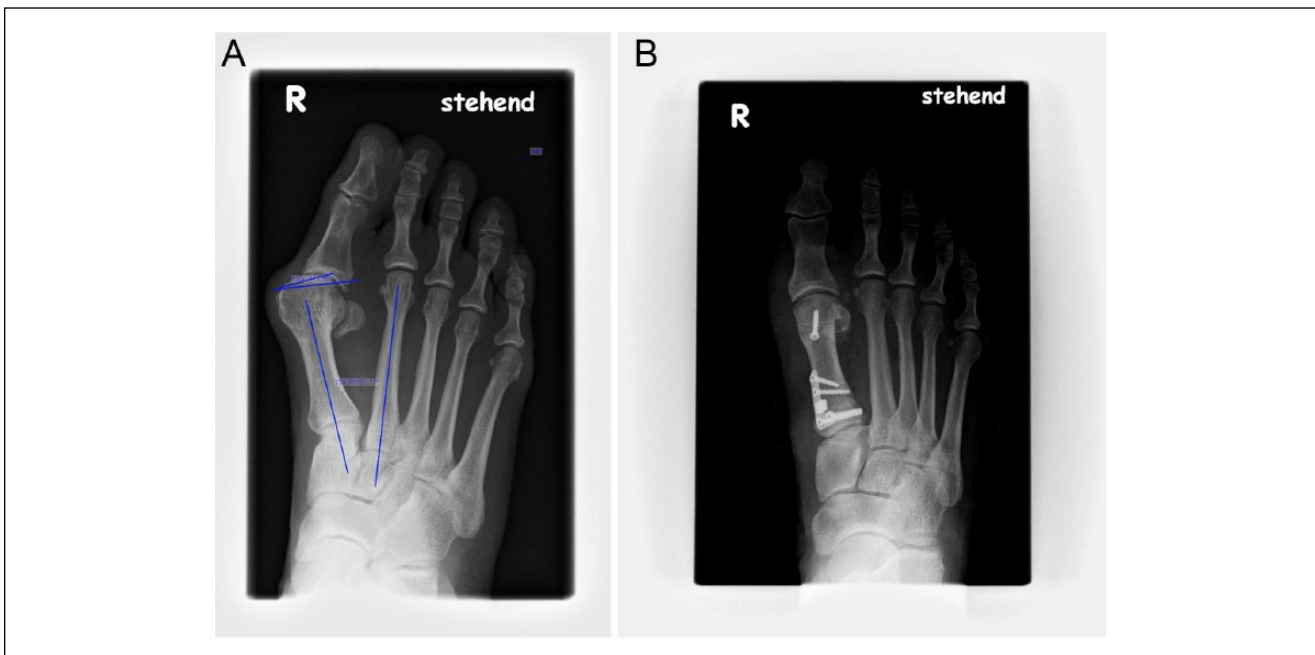


Figure 3. A typical patient with a preop increased IMA and DMAA, corrected well with isometric technique at 5 years postop.

Following the double osteotomy, a capsulorrhaphy was performed to help reposition the sesamoid bones^{15,30} and to stabilize the hallux valgus correction. Biomechanical

findings of distal metatarsal osteotomies accompanied by capsuloligamentous procedures have resulted in more osteotomy stiffness.^{7,28,31}

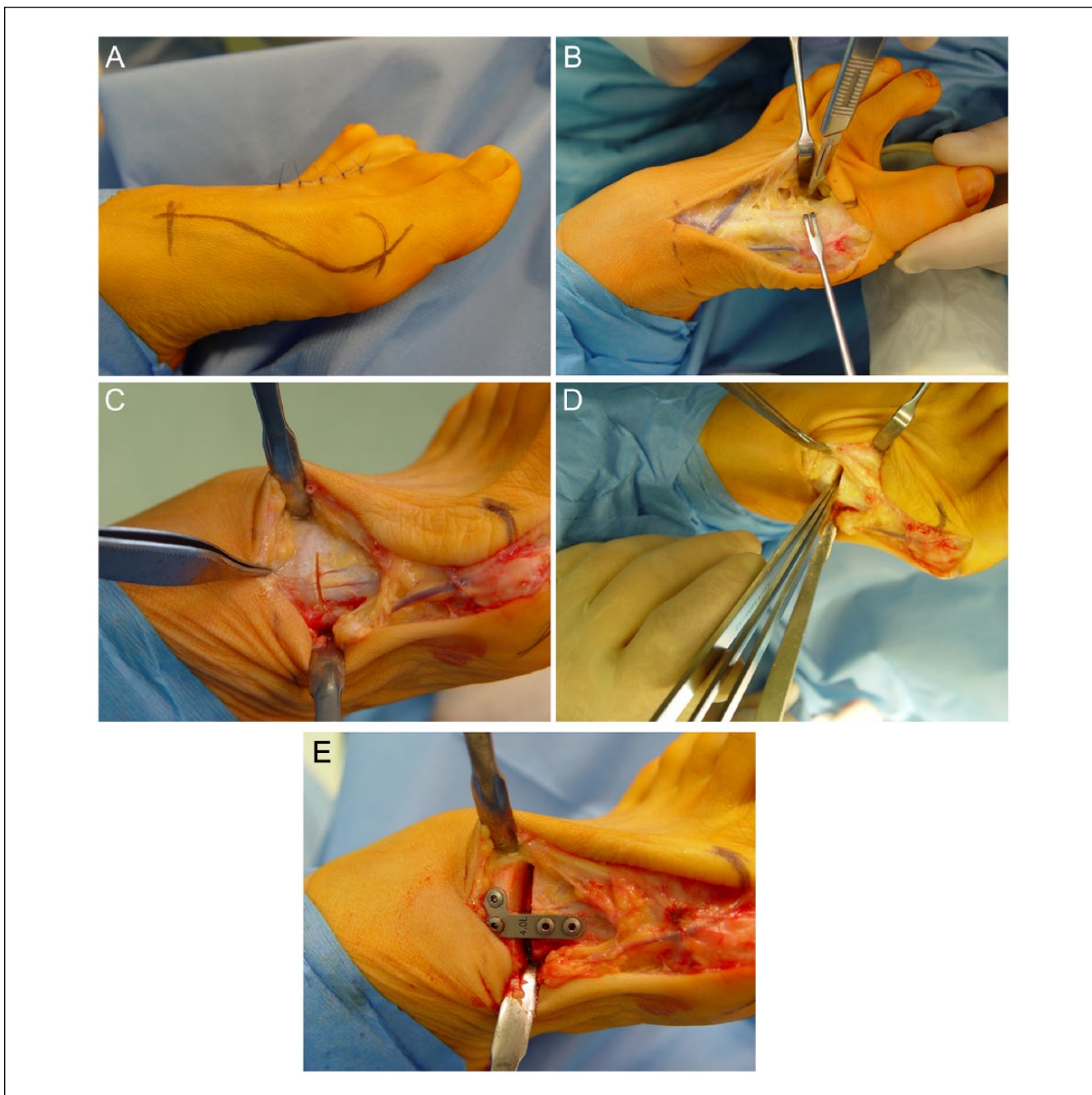


Figure 4. (A) The procedure was performed via a single anteromedial curved incision. (B) In all cases, a lateral release with transection of the adductor tendon from the base of the proximal phalanx and off the lateral aspect of the fibular sesamoids was completed. (C) The proximal osteotomy cut was made approximately 15 mm from the first TMT joint and perpendicular to the metatarsal with a sagittal saw blade. Care was taken to avoid lateral cortical violation. (D) A series of three osteotomies included in the Arthrex set were used to create the opening wedge. (E) The low-profile plate was placed over the medial aspect of the first metatarsal as plantar as possible. The surgeon should check for symmetry of the osteotomy at this point.

Results

The mean 1-2 IMA preoperative was 18.9 degrees (range 17-23 degrees). The mean postoperative angle was 8.6 degrees (range 5-12 degrees), with a mean correction of 10.4

degrees (range 6-16 degrees) (Graph 1). Osteoarthritis was graded in 6 cases as none, in 17 cases as mild, and in 9 cases as moderate. No patients with severe arthritis at the hallux metatarsophalangeal joint were included in this study.

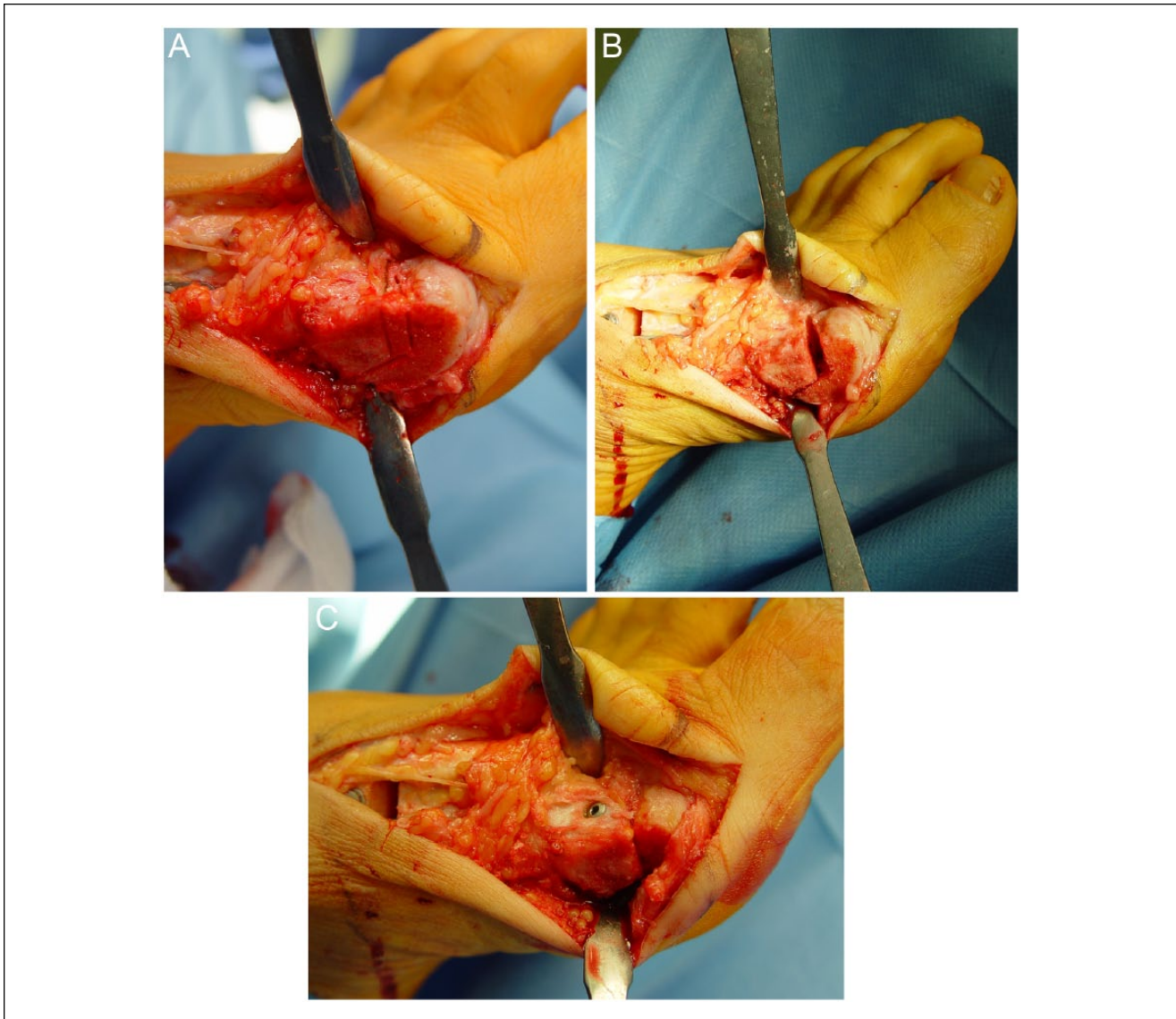


Figure 5. (A) Distally an L-shaped osteotomy (Reverdin-Green) was performed. The medial based wedge should approximate the size of the opening wedge proximally. (B) Wedge removal from the dorsal arm allowed for correction of the DMAA. (C) The distal osteotomy was fixed with either a solid or cannulated screw.

The plates used for fixation of the proximal opening wedge osteotomy ranged from 3 to 5 mm wedges (Graph 2). AOFAS scores were utilized to determine the patient's outcome at final follow-up visit (Graph 3). The results were excellent for each subcategory of the AOFAS scoring system as well as the overall score. In addition, 29/32 patients surveyed at final follow-up stated they would have the procedure again.

Complications

There were 2 cases of partial temporary metatarsal head patchy osteoporosis, which healed without any intervention

after another 3-4 months. We had one patient with intraoperative violation of the lateral cortex at the proximal opening wedge osteotomy site, which healed without incident by simply placing one of the screws across the osteotomy (Figure 7). Shurnas et al came to a similar conclusion in their study showing no ill effect of lateral cortex violation when stable fixation is achieved.³⁰ However care should be taken to prevent plantarflexion or dorsiflexion of the osteotomy if cortical violation is noted.

Only one major complication was noted in a patient who developed painful and chronic lymphedema, treated by manual lymph drainage. There were no cases of nonunion or pseudarthrosis.

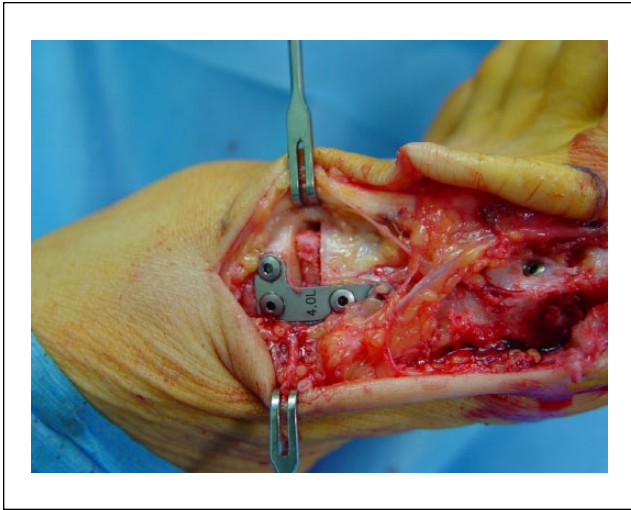
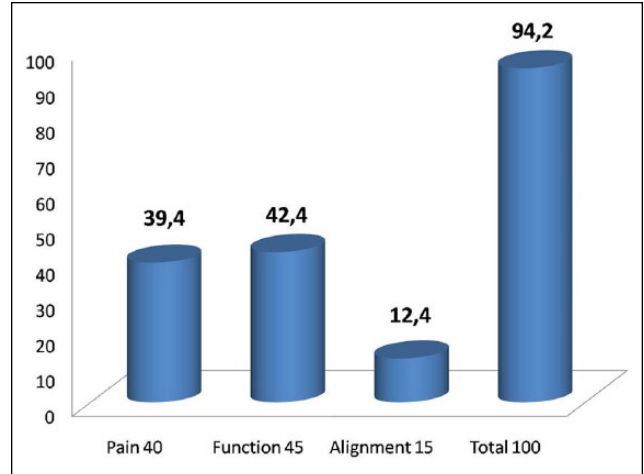
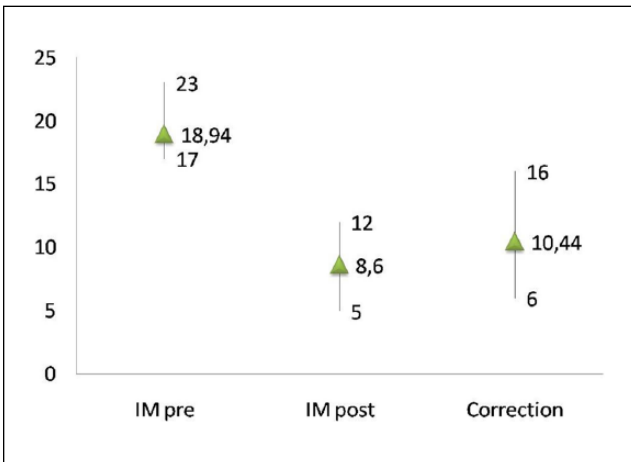



Figure 6. The plate in situ. The gap was filled with cancellous bone from the distal osteotomy or with autologous graft obtained from the calcaneus.



Graph 3. AOFAS score at last follow-up.



Graph 1. Correction of intermetatarsal angle.



Graph 2. The plate most commonly utilized included the 3.5 mm and 4.0 mm wedge constructs. Only 2 patients received a wedge size greater than 4.5 mm and none larger than 5.0 mm.

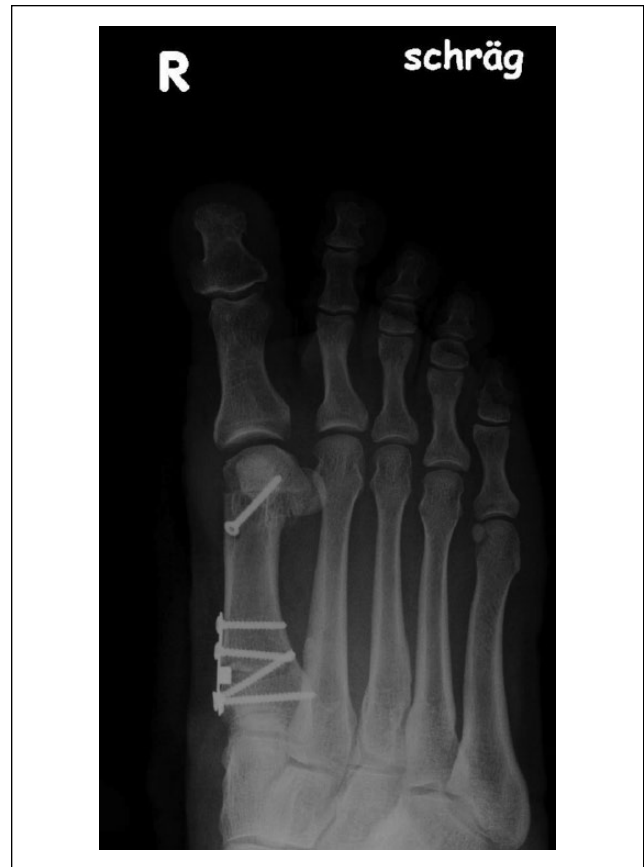

Figure 7. Variation of placing one of the proximal screws in cases of violation of the lateral cortex.

Discussion

In considering treatment options for a patient with hallux valgus, the surgeon has a great number of possible procedures from which to choose. Although conservative

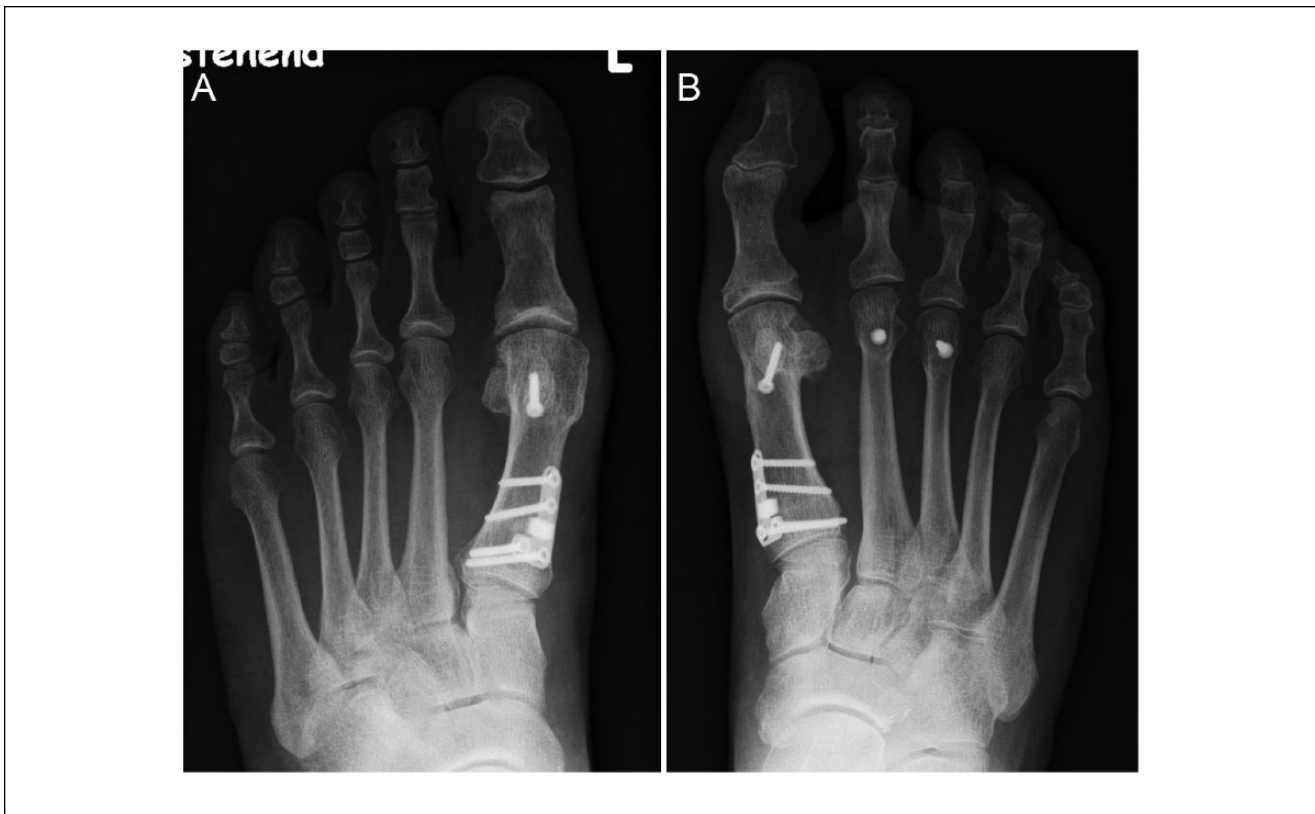

Figure 8. Various cases of 5-year postop X-rays of patients undergoing isometric technique.

management exists, for patients with painful severe hallux valgus deformities, operative correction is often necessary.¹⁰ As Hart et al indicated, there is currently no gold standard for hallux valgus correction.¹¹

In the present study, we showed the benefits of the double osteotomy for moderate to severe hallux valgus deformities, especially those with high DMAAs (Figure 8). The various options for proximal osteotomies have been evaluated and new techniques have been introduced by many authors.^{8,18,29} This study highlights the importance of the distal soft tissue procedure with lateral release of the distal metatarsophalangeal joint, repositioning of the sesamoids and medial capsular reefing, as mentioned by Dalton et al.⁷ Wilson et al³¹ could not find a significant relationship between sesamoid position and patient satisfaction, however. It should be noted that an overzealous lateral release in combination with a distal metatarsal osteotomy may contribute to the development of avascular necrosis of the metatarsal head. The authors now advocate more of a “mini-release” by transecting the adductor tendon and releasing the sesamoid sling without an extensive capsular release.

The development of the low-profile opening wedge plate was inspired by the PUDDU opening wedge plate used for proximal tibial realignment procedures. The plate provides intrinsic stability between the 2-osteotomy walls

and the self-bending small fragment plate. In addition, the plate was easy to place, malleable to the proximal portion of the first metatarsal and interchangeable to allow for the exact amount of opening wedge to correct the IMA. Shurnas et al found that the IMA corrected 2-3 degrees for each 1 mm of opening wedge placed at the proximal metatarsal.³⁰ The plate with its thickness of 0.5 mm is self-bending and creates a self-tensioning system with the osteotomy.

Once adapted, the correction of the first ray is predictable. The lengthening of the first metatarsal with the opening-wedge technique is easily compensated for with the addition of a biplanar chevron osteotomy or Reverdin-Green osteotomy distally, creating an isometric construct. The L-shaped distal chevron closing wedge osteotomy allowed correction of the distal metatarsal intraarticular angle when necessary and, at the same time, shortened the first metatarsal. Because the combined procedure was an isometric technique, there was minimal risk for secondary transfer metatarsalgia or increased pressure in the metatarsophalangeal joint with resulting severe OA (Figure 9). However, care should be taken to avoid overshooting of the first ray, which can result in transfer metatarsalgia.

A scarf osteotomy is an alternative to this double osteotomy, but has its limitations and can be associated with a higher complication rate. The amount of correction is

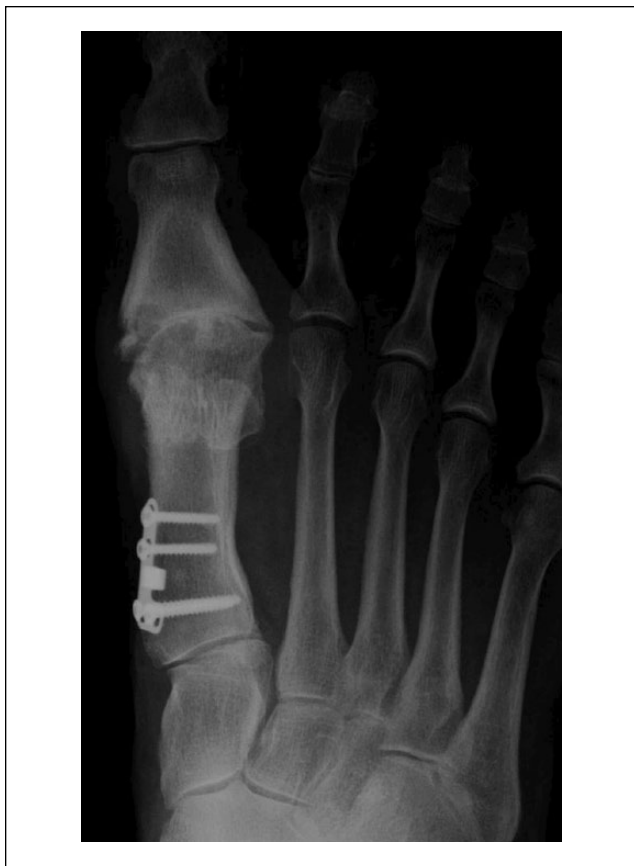

Figure 9. One of the first cases, at that time performed as an isolated proximal opening wedge osteotomy. This X-ray shows the situation 5 years postop. Isolated opening wedge procedures may lead to increased pressures at the hallux metatarsophalangeal joint and resultant arthritis.

limited by the size of the bone,¹⁷ and both deformities (IMA and DMAA) cannot be corrected individually. Although the double osteotomy can be useful in the elderly patient, care should be taken to avoid performing this operation in patients with advanced osteoarthritis.^{19,27}

Conclusion

For treating moderate to severe hallux valgus deformities, the presented double osteotomy technique provides good to excellent results in a majority of patients. It is simple to reproduce with predictable outcomes. Further prospective studies comparing this technique to other commonly employed techniques such as the scarf osteotomy may be useful. In addition, long-term outcomes (>10 years) will be critical in assessing whether there is a higher incidence of arthrosis at the hallux metatarsophalangeal joint in those patients who undergo a proximal opening wedge as a solitary procedure versus those receiving a double osteotomy.

Declaration of Conflicting Interests

The author(s) declared no potential conflicts of interest with respect to the research, authorship, and/or publication of this article.

Funding

The author(s) received no financial support for the research, authorship, and/or publication of this article.

References

1. Acevedo JI. Fixation of metatarsal osteotomies in the treatment of hallux valgus. *Foot Ankle Clin.* 2000;5(3):451-468.
2. Acevedo JI, Sammarco VJ, Boucher HR, et al. Mechanical comparison of cyclic loading in five different first metatarsal shaft osteotomies. *Foot Ankle Int.* 2002;23(8):711-716.
3. Bozkurt MC, Tigar C, Dalstra M, et al. Stability of a cannulated screw versus a Kirschner wire for the proximal crescentic osteotomy of the first metatarsal: a biomechanical study. *J Foot Ankle Surg.* 2004;43(3):138-143.
4. Canseco KL, Rankine L, Long J, et al. Motion of the multi-segmental foot in hallux valgus. *Foot Ankle Int.* 2010;31(2):146-152.
5. Christensen JC, Jennings MM. Normal and abnormal function of the first ray. *Clin Podiatr Med Surg.* 2009;26(3):355-371.
6. Coughlin MJ, Carlson RE. Treatment of hallux valgus with an increased distal metatarsal articular angle: evaluation of double and triple first ray osteotomies. *Foot Ankle Int.* 1999;20(12):762-770.
7. Dalton SK, Bauer GR, Lamm BM, et al. Stability of the offset V osteotomy: effects of fixation, orientation, and surgical translocation in polyurethane foam models and preserved cadaveric specimens. *J Foot Ankle Surg.* 2003;42(2):53-62.
8. De Lavigne CQ, Rasmont Q, Hoang B, et al. Percutaneous double metatarsal osteotomy for correction of severe hallux valgus deformity. *Acta Orthop Belg.* 2011;77(4):516-521.
9. Easley ME, Trnka HJ. Current concepts review: hallux valgus part 1: pathomechanics, clinical assessment, and nonoperative management. *Foot Ankle Int.* 2007;28(5):654-659.
10. Glasoe WM, Nuckley DJ, Ludewig PM, et al. Hallux valgus and the first metatarsal arch segment: a theoretical biomechanical perspective. *Phys Ther.* 2010;90(1):110-120.
11. Hart ES, deAsla RJ, Grottkau BE, et al. Current concepts in the treatment of hallux valgus. *Orthop Nurs.* 2008;27(5):274-280.
12. Hofstaetter SG, Glisson RR, Alitz CJ, et al. Biomechanical comparison of screws and plates for hallux valgus opening-wedge and Ludloff osteotomies. *Clin Biomech (Bristol, Avon).* 2008;23(1):101-108.
13. Jones C, Coughlin M, Petersen W, et al. Mechanical comparison of two types of fixation for proximal first metatarsal crescentic osteotomy. *Foot Ankle Int.* 2005;26(5):371-374.
14. Jung HG, Guyton GP, Parks BG, et al. Supplementary axial Kirschner wire fixation for crescentic and Ludloff proximal metatarsal osteotomies: a biomechanical study. *Foot Ankle Int.* 2005;26(8):620-626.

15. Kaiman ME, Piccora R. Tibial sesamoidectomy: a review of the literature and retrospective study. *J Foot Surg.* 1983;22(4):286-289.
16. Kernozek TW, Sterriker SA. Chevron (Austin) distal metatarsal osteotomy for hallux valgus: comparison of pre- and post-surgical characteristics. *Foot Ankle Int.* 2002;23(6):503-508.
17. Kumar S, Konan S, Oddy MJ, et al. Basal medial opening wedge first metatarsal osteotomy stabilized with a low profile wedge plate. *Acta Orthopædica Belgica.* 2012;78(3):362-368.
18. Lechler P, Feldmann C, Köck FX, et al. Clinical outcome after chevron-Akin double osteotomy versus isolated chevron procedure: a prospective matched group analysis. *Arch Orthop Trauma Surg.* 2012;132:9-13.
19. Neese DJ, Zelent ME. The modified Mau-Reverdin double osteotomy for correction of hallux valgus: a retrospective study. *J Foot Ankle Surg.* 2009;48(1):22-29.
20. Newman AS, Negrine JP, Zecovic M, et al. A biomechanical comparison of the Z step-cut and basilar crescentic osteotomies of the first metatarsal. *Foot Ankle Int.* 2000;21(7):584-587.
21. Popoff I, Negrine JP, Zecovic M, et al. The effect of screw type on the biomechanical properties of scarf and crescentic osteotomies of the first metatarsal. *J Foot Ankle Surg.* 2003;42(3):161-164.
22. Sammarco VJ. Surgical correction of moderate and severe hallux valgus: proximal metatarsal osteotomy with distal soft-tissue correction and arthrodesis of the metatarsophalangeal joint. *Instr Course Lect.* 2008;57:415-428.
23. Shaw N, Wertheimer S, Krueger J, et al. A mechanical comparison of first metatarsal diaphyseal osteotomies for the correction of hallux abducto valgus. *J Foot Ankle Surg.* 2001;40(5):271-276.
24. Siekmann W. Erste Erfahrungen mit einem neuen Implantat zur proximalen open wedge-Osteotomie des Os metatarsale I varus. *FussSprungg.* 2008;1:283-288.
25. Smith BW, Coughlin MJ. Treatment of hallux valgus with increased distal metatarsal articular angle: use of double and triple osteotomies. *Foot Ankle Clin.* 2009;14(3):369-382.
26. Stephens MM. Does shortening of the first ray in the treatment of adolescent hallux valgus prejudice the outcome? *J Bone Joint Surg Br.* 2006;88(7):858-859.
27. Tollison ME, Baxter DE. Combination chevron plus Akin osteotomy for hallux valgus: should age be a limiting factor? *Foot Ankle Int.* 1997;18(8):477-481.
28. Uchiyama E, Kitaoka HB, Luo ZP, et al. Pathomechanics of hallux valgus: biomechanical and immunohistochemical study. *Foot Ankle Int.* 2005;26(9):732-738.
29. Unal AM, Baran O, Uzun B, et al. Comparison of screw-fixation stabilities of first metatarsal shaft osteotomies: a biomechanical study. *Acta Orthop Traumatol Turc.* 2010;44(1):70-75.
30. Shurnas PS, Watson TS, Crislip TW. Proximal first metatarsal opening wedge osteotomy with a low profile plate. *Foot Ankle Int.* 2009;30(9):865-872.
31. Wilson JD, Baines J, Siddique MS, et al. The effect of sesamoid position on outcome following scarf osteotomy for hallux abducto valgus. *Foot Ankle Surg.* 2009;15(2):65-68.
32. Yu GV, Johng B, Freireich R, et al. Surgical management of metatarsus adductus deformity. *Clin Podiatr Med Surg.* 1987;4(1):207-232.